Adult Patient with suspected chest wall trauma and no indication for WBCT

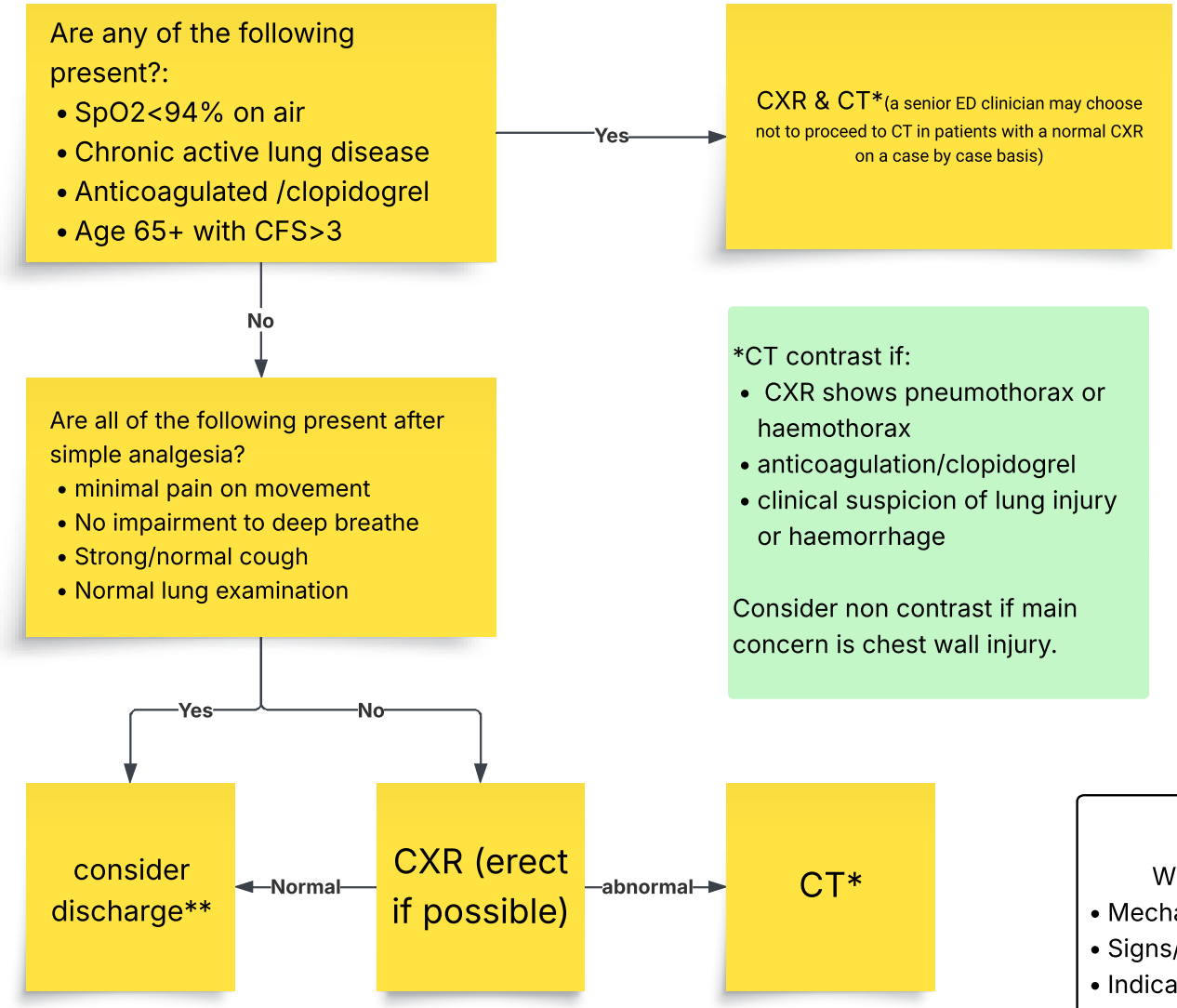

*CT contrast if:

- CXR shows pneumothorax or haemothorax
- anticoagulation/clopidogrel
- clinical suspicion of lung injury or haemorrhage

Consider non contrast if main concern is chest wall injury.

**patients requiring admission for chest wall trauma should recieve a CT

TRAK Imaging request

Write "*trauma*" and include:

- Mechanism
- Signs/symptoms
- Indication as per flowchart
- Injuries suspected

Kerslake, Moncur, Armstrong, Blankenstein, Macmillan. Jan 2026. Review Jan 2027